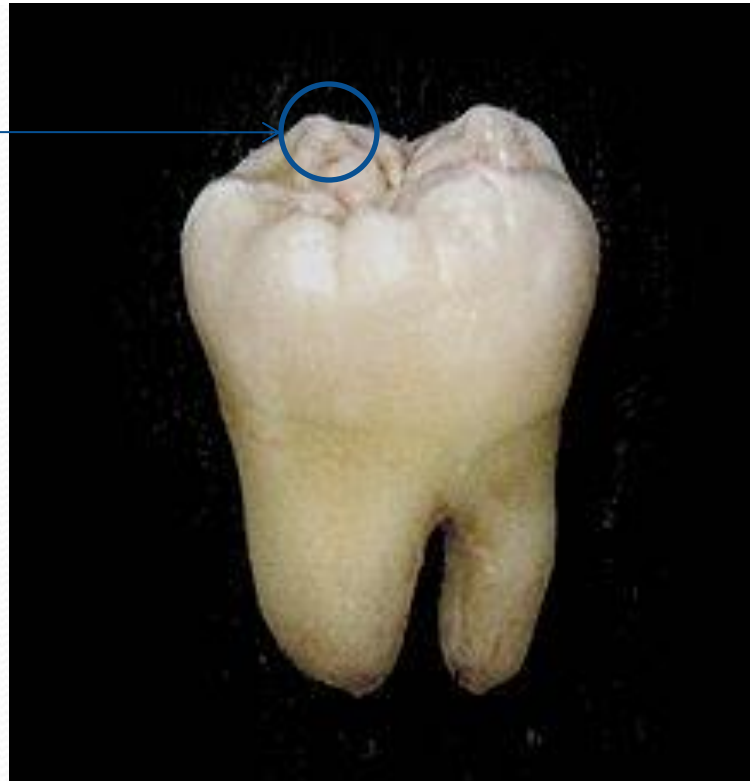
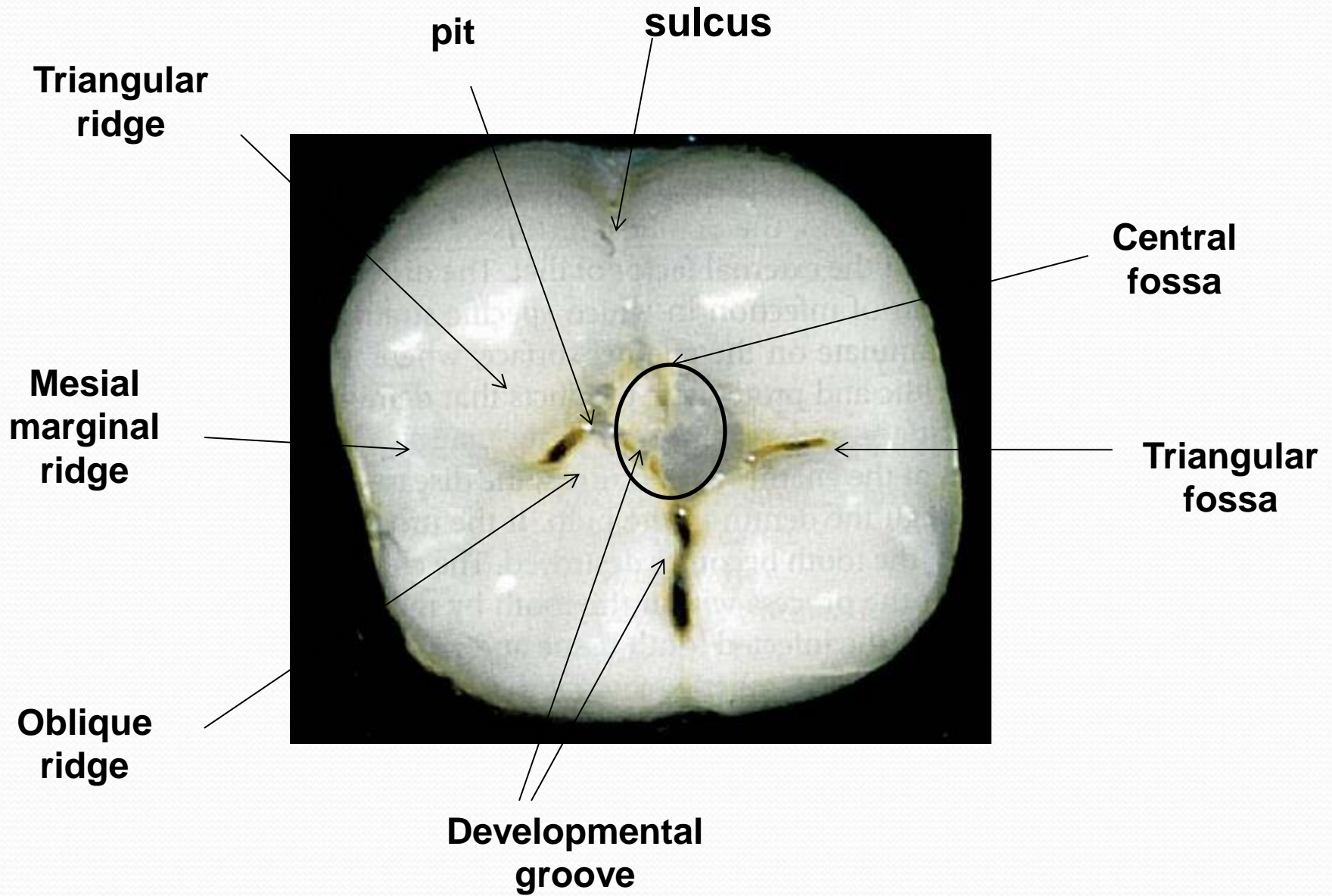


Anatomical landmarks

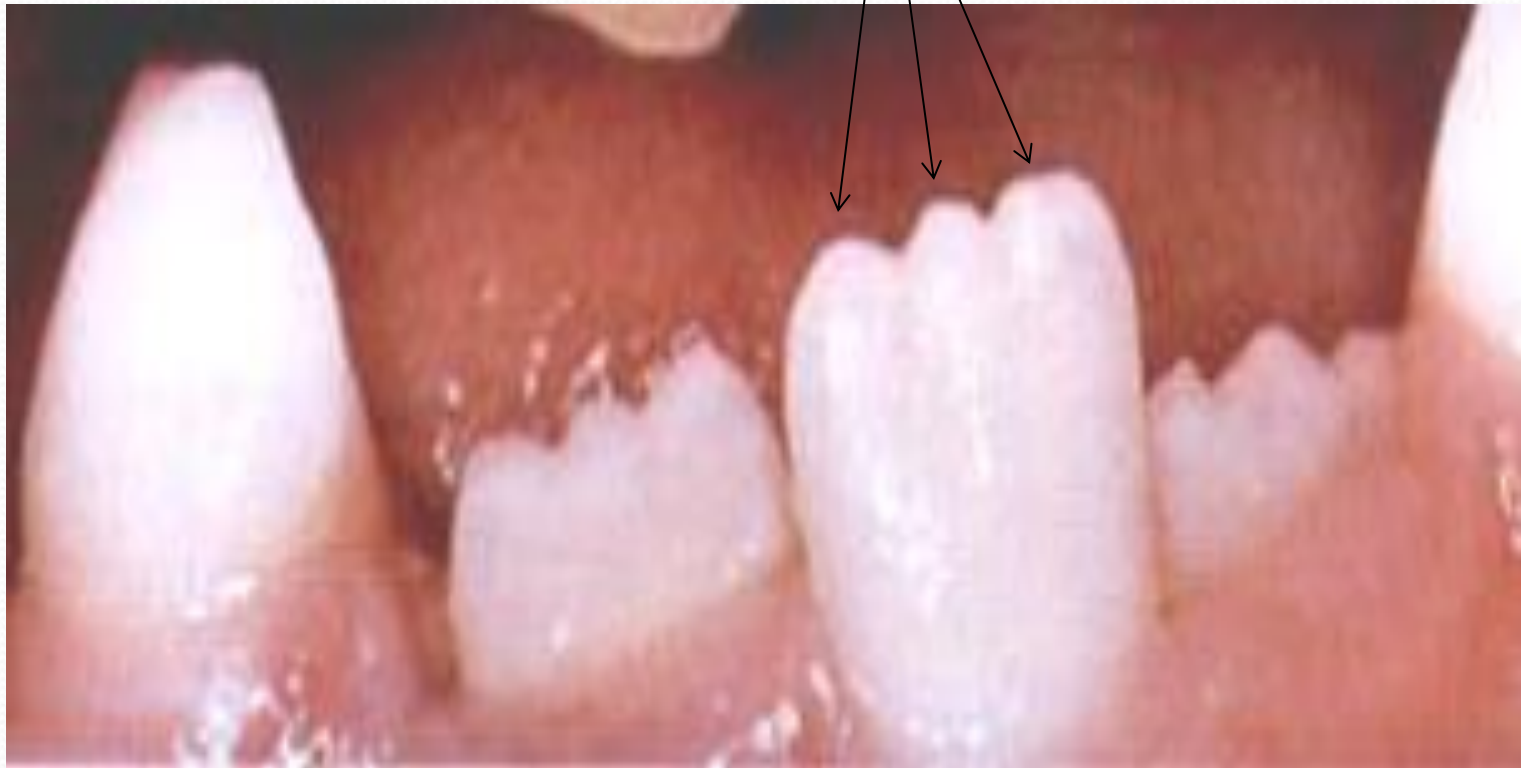In order to study an individual tooth intelligently, we must be able to recognize all landmarks of importance by name. these include:

Cusp






mamelons



- (1) Cusp: it is an elevation or mound on the crown portion of a tooth making up a divisional part of the occlusal surface.
- (2) Cingulum {Latin word for girdle}: it is the lingual lobe of an anterior tooth.
- It makes up the bulk of the cervical third of lingual surface. Its convexity mesiodistally resembles a girdle encircling the lingual surface at the cervical third.
- (3) Tubercle: it is a small elevation on some portion of the crown produced by an extra formation of enamel. Tubercles are deviation from the typical form.

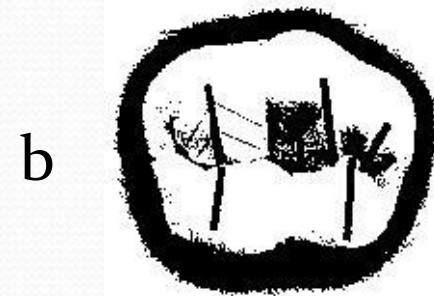

1



2




- (4) Ridge : it is any linear elevation on the surface of the tooth and is named according to its location (e.g. *buccal ridge, incisal ridge, marginal ridge*).
- (a) Marginal ridges: these are rounded borders of the enamel that form the mesial and distal margins of the occlusal surfaces of premolars and molars and the mesial and distal margins of the lingual surfaces of the incisors and canines.
- (b) Triangular ridges: these descend from the tips of the cusps of molars and premolars toward the central part of the occlusal surfaces. they are so named because the slopes of each side of the ridge are inclined to resemble two sides of a triangle. They are named after the cusps to which they belong, (e.g. the triangular ridge of the buccal cusp of maxillary first premolar).



(c) Transverse ridge: it is the union of two triangular ridges crossing transversely the surface of posterior tooth.

(d) Oblique ridge: it is a ridge crossing obliquely the occlusal surfaces of maxillary molars. it is formed by the union of the triangular ridge of the distobuccal cusp and the distal cusp ridge of the mesiolingual cusp.



(5) Fossa: it is an irregular depression or concavity.

(a) Lingual fossa: it is located on the lingual surface of anterior teeth.

(b) Central fossa: it is located on the occlusal surface of molars.

(c) Triangular fossa: it is located on the occlusal surfaces of molars and premolars, mesial or distal to marginal ridges.


a





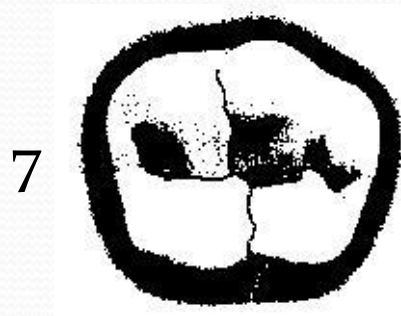

b



c




- (6) **Sulcus:** it is a long depression or valley in the surface of a tooth between ridges and cusps, the inclines of which meet at an angle. A sulcus has a developmental groove at the junction of its inclines.
- (7) **Developmental groove:** it is a shallow groove or line between the primary parts of the crown or root.
- (8) **Supplemental groove:** it is a less distinct, shallow linear depression on the surface of the tooth, but is supplemental to a developmental groove and does not mark the junction of primary parts.
- (9) **pit:** it is a small pin point depression located at the junction of developmental grooves or at terminals of those grooves, e.g. central pit is a term used to describe a landmark in the central fossa of molars where developmental grooves join.



- (10) Mamelon: it is any one of the three protuberances found on the incisal edge of newly erupted incisor teeth.
- (11) Lobe: it is one of the primary sections of formation in the development of the crown. Cusps and mamelons are representative of lobes.

10





Great Thanks